International Journal of Medical and Pharmaceutical Sciences
Open access peer-reviewed Journal
Volume 2, Issue 11, Page 276-288.
https://doi.org/10.5281/zenodo.24579676

Research Article

Monkeypox Virus: From Viral Pathogenesis and Transmission Dynamics to Emerging Therapeutics and Vaccines

Shashank K.[1*], Bhanunandana G. S.[1], Bhargav Shankar Naik[1], Smithan B. R.[1], Dr. M. Mallikarjuna Gouda[2]

[1] Graduate Student, Prasanna College of Pharmacy, Laila, Belthangady (Po), Dakshina Kannada, Karnataka, India-574214.
[2] Principal, Department of Pharmaceutics, Prasanna College of Pharmacy, Laila, Belthangady (Po), Dakshina Kannada, Karnataka, India-574214.

Monkeypox virus (mpox), a double-stranded DNA orthopoxvirus, has emerged as a significant public health threat, evolving from an endemic zoonosis in Central and West Africa into a global emergency. This review summarizes the virus's history, structural architecture, replication cycle, pathophysiology, clinical presentation, transmission modes, complications, diagnostics, and management strategies. Structurally, monkeypox possesses an ovoid viral morphology enclosing a genome, operating through cytoplasmic replication that yields intracellular mature virions (IMVs) and extracellular enveloped virions (EEVs) equipped with specific surface proteins for host invasion and immune evasion. Clinical manifestations present after an incubation period of 5–21 days, characterized by prodromal symptoms followed by systemic cutaneous lesions that progress through macules, papules, vesicles, pustules, and desquamation. While transmission historically occurred via animal contact, recent global outbreaks demonstrate sustained human-to-human transmission primarily through close physical, sexual, or respiratory contact. Severe complications include neurological disorders, extensive dermatological distress, cardiovascular involvement, secondary bacterial sepsis, and ocular lesions. Accurate diagnosis relies on molecular polymerase chain reaction (PCR) assays, complemented by electron microscopy and serological tests. Treatment combines supportive care with targeted antiviral therapeutics, notably tecovirimat and cidofovir/brincidofovir. Disease prevention and outbreak control heavily depend on targeted vaccination strategies utilizing second- and third-generation vaccines, such as ACAM2000, MVA-BN, and LC16m8. Continuous surveillance and robust clinical management remain critical to mitigating future resurgence.

Keywords: Monkeypox Virus, Viral Pathogenesis, Transmission Dynamics, Emerging Therapeutics, Vaccines

INTRODUCTION:

Monkeypox is a viral zoonosis caused by a double-stranded DNA pathogen within the genus Orthopoxvirus (family *Poxviridae,* subfamily *Chordopoxvirinae)*. Following infection, the host's immune response serves as a critical determinant of viral pathogenesis, disease severity, and overall clinical presentation. Cutaneous lesions represent the primary clinical manifestation of monkeypox virus infection and remain a central focus of ongoing outbreak surveillance. The accompanying inflammatory response can precipitate severe downstream complications, ranging from localized deep tissue abscesses to respiratory compromise and organ dysfunction. Recently, increased emphasis has been placed on understanding the dynamics of person-to-person transmission. The monkeypox virus spreads through close physical contact with infected humans, animal reservoirs, or contaminated surfaces. Due to its dual capacity for zoonotic spillover and human-to-human propagation, the World Health Organization issued a global health emergency declaration focusing on out-

breaks in Africa. Timely diagnosis depends on identifying prodromal signs-such as lymphadenopathy, fever, headache, and myalgia-and confirming viral presence via standard or Reverse Transcription Polymerase Chain Reaction testing. [1]



Figure 1: Monkey Pox

History:

Human monkeypox was first documented in a nine-month-old infant in the Democratic Republic of the Congo in 1970. The virus subsequently attracted major global attention during 2003–2004 following its initial recorded outbreak in the United States. Despite its historical nomenclature, monkeypox is not primarily harbored or transmitted by macaques; rather, various small mammals and rodents are implicated in its zoonotic cycle, though the reservoir host remains elusive. Crucially, viral activity was exclusively documented in non-human hosts prior to 1970. Following the eradication of smallpox, human susceptibility to monkeypox increased significantly. The cessation of mass smallpox immunization campaigns resulted in an expanding pool of unvaccinated individuals, thereby accelerating viral incidence during the post-eradication era. This historical perspective shifted following the 2003 US outbreak, which demonstrated that monkeypox exhibited higher human-to-human transmissibility and produced greater viral loads in infected patients than previously recognized. Although historically regarded as a regional disease confined largely to Africa, monkeypox demonstrated a marked shift in global distribution, predominantly affecting populations in Europe and the Western Hemisphere. [2]

Epidemiology:

Early surveillance data from West and Central Africa indicated 59 human cases within the first ten years of disease recognition (1970–1980). During this period, young children (<10 years) experienced substantial mortality, with a case fatality rate of 17%. Surveillance by the WHO underscored the risk of rising population susceptibility to monkeypox amid declining smallpox immunity. Over the two decades following 2000, endemic regions saw dramatic shifts: the DRC recorded three spatiotemporal clusters including 760 confirmed cases from 2005 to 2007 and a 20-fold incidence jump (0.72 to 14.42 per 10,000) when compared to 1981–1986 data. Similarly, Nigeria saw a prominent re-emergence in 2017 after a gap of nearly four decades. According to a 2022 World Health Organization report, monkeypox was categorized as endemic across multiple African nations, including Benin, Cameroon, the Central African Republic, the Democratic Republic of the Congo (DRC), Gabon, Côte d'Ivoire, Liberia, Nigeria, Sierra Leone, South Sudan, and Ghana (where detection was limited to animal populations). During the early months of 2022 (January to May), the DRC bore the highest disease burden, recording 1,284 suspected cases and 58 fatalities. Outside endemic African boundaries, viral spillover events and limited clusters have been periodically documented in non-endemic countries (e.g., the UK, USA, Israel, and Singapore) following animal trade or human travel. A landmark example occurred in 2003, when contact with imported African rodents led to 71 human infections (35 confirmed) via infected pet prairie dogs in the United States. Travel-related importations continued in subsequent years: the UK identified seven cases from 2018 to 2021 (four linked to travel), and the US confirmed two separate cases in July 2021 among travelers returning from Nigeria to Texas and Maryland. The 2022 global monkeypox outbreak gained international attention in May 2022 when initial cases were reported to the World Health Organization (WHO). Early transmission was heavily clustered among attendees of an international LGBT+ Pride festival in Gran Canaria, Spain, triggering secondary chains across multiple European nations. However, sustained local and community-level transmission rapidly superseded imported cases worldwide within weeks. Recognizing its rapid expansion and global risk, the WHO formally designated the outbreak a Public Health Emergency of International Concern (PHEIC) on July 23, 2022. [3]

Money pox life cycle:

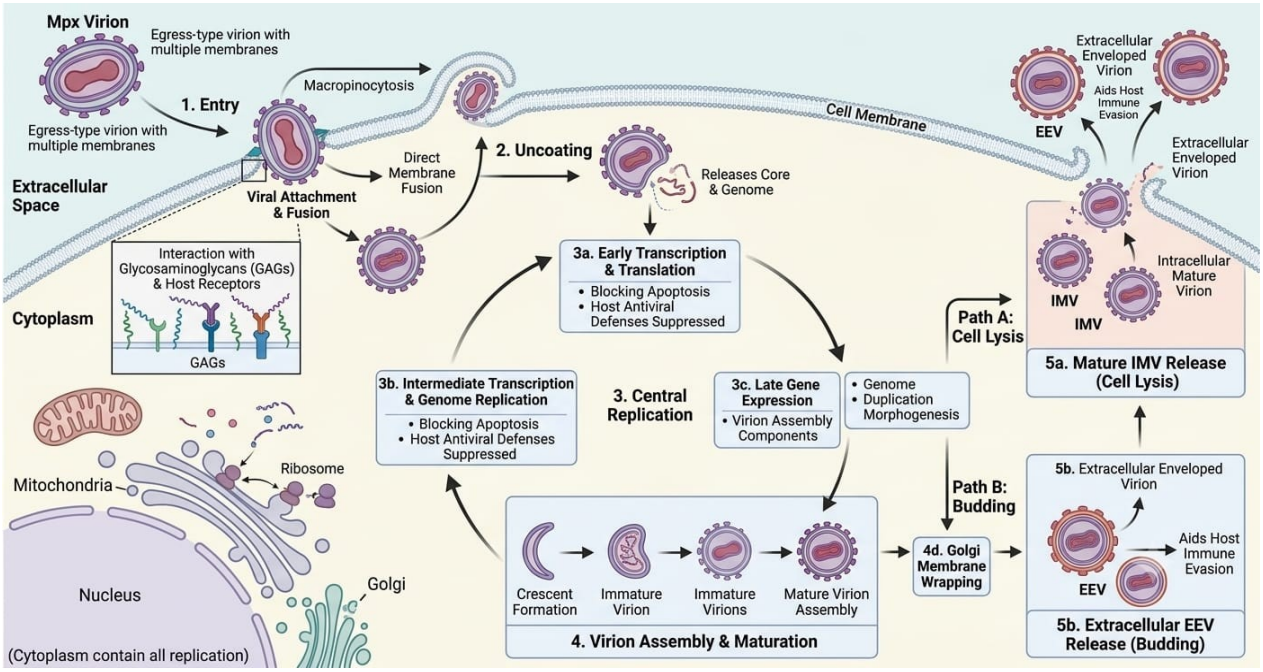

Figure 2: Life Cycle of Monkey Pox

Monkeypox virus replicates exclusively in the cytoplasm, following a lifecycle typical of Orthopoxviruses. Infection begins when viral surface proteins engage host receptors, triggering entry through direct membrane fusion or macropinocytosis. Following entry, the release of the viral core enables early transcription and translation of proteins that suppress host cellular control. Genome replication occurs post-uncoating, driving late-stage protein synthesis necessary for virion assembly. Finally, mature particles undergo morphogenesis before release: cell lysis frees intracellular mature virions (IMVs), whereas extracellular enveloped virions (EEVs) acquire a host membrane envelope during budding, aiding in host immune evasion. Viral entry is initiated through the interaction of viral particles with host cell glycosaminoglycans (GAGs), driving internalization and fusion via macropinocytosis. Post-entry uncoating releases the viral genome into the cytoplasm, triggering sequential gene expression: early transcription generates proteins that establish an optimal replicative environment by blocking apoptosis and host antiviral defenses, intermediate transcription drives genome duplication and structural morphogenesis, and late gene expression supplies components essential for virion assembly. Following assembly, mature virions undergo Golgi membrane wrapping before egress to complete the cycle.

Structure of monkeypox:

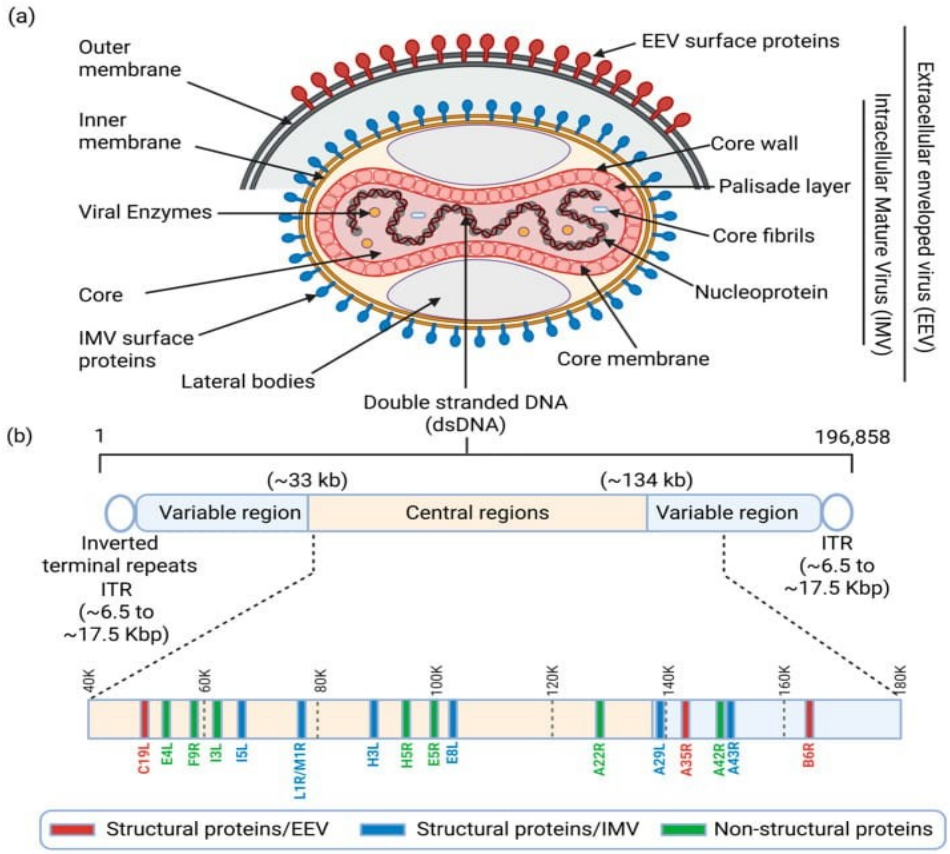

Figure 3: Structure of Monkeypox

Monkeypox virus particles exhibit a characteristic ovoid or brick-shaped morphology (~200–250 nm) and harbor a ~197.2 kb dsDNA genome containing >190 ORFs involved in viral fitness, pathogenesis, and immune modulation. Infection initiates through binding to host surface glycosaminoglycans (e.g., chondroitin and heparan sulphate), culminating in replication, assembly, and virion egress. Replication produces two functional infectious forms with distinct tropisms and entry mechanisms. Intracellular mature virions (IMVs), decorated with critical envelope-stabilizing surface proteins (A29L, A43R, H3L, E8L, I5L, and L1R/M1R) (Figure 3b), are liberated upon cell lysis, entry occurring via macropinocytosis to facilitate inter-host transmission. Conversely, extracellular enveloped virions (EEVs) acquire an additional Golgi- or endosome-derived outer membrane containing proteins such as C19L, A35R, and B6R (Figure 3a). Released via exocytosis, EEVs invade adjacent cells via direct membrane fusion, predominantly driving efficient intra-host dissemination monkeypox virus encodes a suite of non-structural proteins-including A22R, A42R, E4L, E5R, F9R, H5R, and I3L - that are omitted from the final virion structure (Figure 3b) yet govern critical aspects of infection, replication, and host defense suppression. Mechanistically, A42R triggers viral DNA synthesis, while A22R and F9R contribute structurally and functionally to the core replication machinery. Replication efficiency is further optimized by E5R and H5R, which interact with host cellular machinery to regulate lifecycle progression. Additionally, I3L contributes broadly to replication and virion assembly, whereas E4L directly impairs host innate immunity by disrupting interferon (IFN) signaling pathways. The viral core comprises the dsDNA genome and associated core fibrils, which are enclosed within a highly organized proteinaceous palisade layer that defines the core boundary (Figure 3b). The genome consists of a conserved central region flanked by variable terminal domains (Figure 3b). A characteristic feature is the presence of inverted terminal repeats (ITRs), which extend approximately 6.5–17.5 kb at both genomic termini. These terminal regions form covalently closed hairpin structures, resulting in the absence of conventional free 3′ and 5′ ends and contributing to genome stability (Figure 3b). The conserved central region encodes viral factors essential for transcription, genome replication, and virion assembly. [4]

Pathophysiology and virulence:

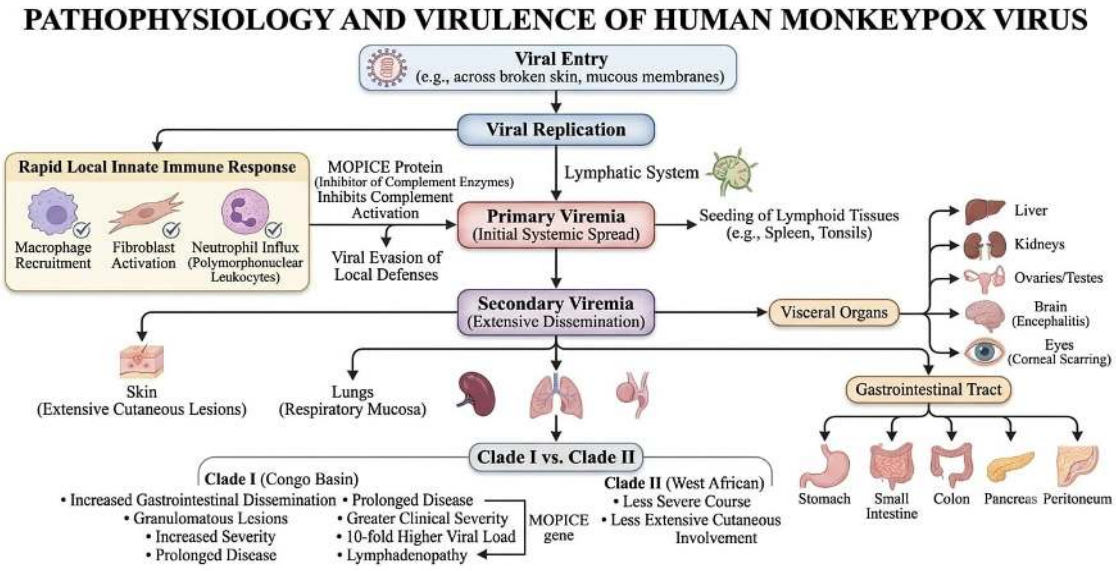

Figure 4: Pathophysiology and Virulence of Human Monkey Pox

Current knowledge of the pathophysiology of human monkeypox is derived from human clinical and modeling studies, epidemiological investigations of outbreaks, and experimental challenge studies in nonhuman primates and prairie dogs. Following an incubation period of approximately 5–21 days, most infected individuals develop clinical manifestations, with symptoms typically emerging within 7–14 days (Figure 4). Following viral entry through the skin, soft tissues, upper respiratory tract mucosa, or lungs, a rapid local innate immune response is initiated over several hours to days. This response is characterized by the recruitment of macrophages, fibroblasts, and polymorphonuclear leukocytes to the site of infection. Nevertheless, monkeypox virus can overcome these initial host defenses and establish systemic infection. Viral dissemination subsequently occurs through the lymphatic system, reaching regional lymph nodes and resulting in an initial viremic phase characterized by viral seeding of the spleen and tonsillar tissues. A subsequent secondary viremic phase facilitates dissemination to the skin and visceral organs, including the liver, intestines, kidneys, ovaries, testes, and brain. Ocular involvement may result in corneal scarring, either through infection of the conjunctiva or eyelids or through autoinoculation following contact with infectious cutaneous lesions. Compared with clade II (formerly designated the West African clade), infection with clade I (formerly the Central African clade) is generally associated with more extensive cutaneous involvement, increased gastrointestinal tract dissemination with granulomatous lesions involving the stomach, small intestine, colon, pancreas, and peritoneum, prolonged disease duration, greater clinical severity, and substantially higher plasma viral loads, reported to be approximately 10-fold greater. The histopathological and clinical manifestations of human monkeypox closely resemble those observed in smallpox; however, monkeypox is generally associated with a less severe clinical course, whereas lymphadenopathy is a characteristic feature of monkeypox but is typically absent in smallpox. Inoculation through an animal bite or scratch may facilitate direct viral entry into the bloodstream, potentially shortening the incubation period and resulting in minimal or absent prodromal manifestations. The greater virulence of clade I has been attributed, in part, to the presence of several virulence-associated genes that are absent from clade II. Among these, the monkeypox inhibitor of complement enzymes (MOPICE) gene is particularly notable because of its functional similarity to the smallpox inhibitor of complement enzymes (SPICE) encoded by variola virus. MOPICE encodes a protein that interferes with the early stages of the host complement cascade, thereby facilitating viral immune evasion. Additional clade I–associated virulence determinants have been implicated in promoting cellular apoptosis and enhancing disease severity. Consistent with these enhanced virulence properties, clade I infection has been associated with

earlier onset of viremia and more extensive systemic dissemination. [5]

Symptoms:

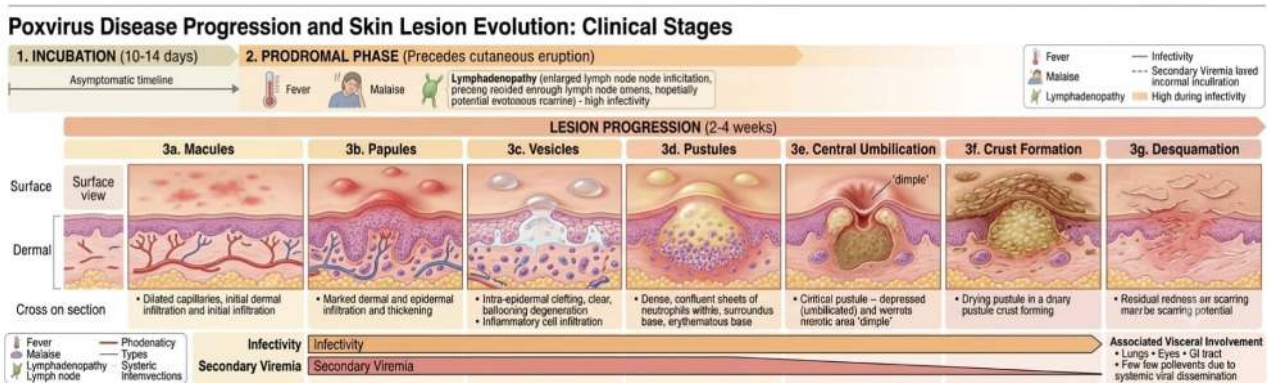

Figure 5: Symptoms of Monkey Pox

Following an incubation period of approximately 10–14 days, most individuals develop a prodromal phase characterized by fever, malaise, and lymphadenopathy, which generally precedes the onset of the characteristic cutaneous eruption. Additional systemic manifestations may include chills, sweating, headache, back pain, sore throat, cough, and dyspnea. Over the subsequent 2 - 4 weeks, the skin lesions progress through successive stages, beginning with macules and evolving into papules, vesicles, and pustules, followed by central umbilication, crust formation, and desquamation. During the prodromal phase, secondary viremia facilitates viral dissemination from lymphoid tissues to the skin and visceral organs, including the lungs, eyes, and gastrointestinal tract. This phase is considered a period of high infectivity and may contribute substantially to person-to-person transmission. [6]

Clinical presentation:

The incubation period of monkeypox virus infection ranges from 5 to 21 days, with transmissibility generally beginning after the onset of clinical manifestations. The clinical course is broadly characterized by a prodromal phase followed by a cutaneous eruption. The prodromal phase typically lasts 0–2 days and is marked by fever, fatigue, severe headache, lymphadenopathy, and myalgia. The subsequent rash usually develops within 1–5 days after fever onset and persists for approximately 2–4 weeks, although the overall rash phase may extend for 7–21 days. Lesions predominantly affect the face and extremities, with reported involvement of the face (95%), palms and soles (75%), oral mucosa (70%), genital tract (30%), and conjunctiva (20%). The lesions undergo a characteristic sequential evolution from macules and papules to vesicles, pustules, crusts, and eventual desquamation. Lymphadenopathy is a prominent clinical feature of monkeypox virus infection, occurring in approximately 84% of unvaccinated and 54% of vaccinated individuals. It may be unilateral or bilateral and commonly involves the submandibular, cervical, postauricular, axillary, and inguinal lymph nodes. Severe disease may be complicated by central nervous system involvement and upper airway compromise secondary to pronounced lymphadenopathy. Additional complications include post-inflammatory hyperpigmentation, cutaneous scarring, dehydration, and secondary bacterial infections, which may progress to septicemia. [7]

Infection and transmission route:

The skin and mucocutaneous surfaces constitute important sites of infection and transmission. Human-to-human transmission may occur through prolonged close-range exposure to respiratory secretions, as respiratory droplets generally have limited dispersal distances and are unlikely to support transmission without sustained face-to-face contact. Although monkeypox is not traditionally regarded as a sexually transmitted infection, intimate and sexual contact, particularly among men who have sex with men, has been identified as an important mode of transmission during recent outbreaks. Monkeypox virus has been detected in semen, genital and rectal lesions, as well as saliva and fecal specimens from confirmed cases, although the contribution of these biological fluids to transmission remains incompletely established. Zoonotic transmission can occur through bites or

scratches from infected animals and through direct contact with infected live or deceased animals or their bodily fluids. Person-to-person transmission predominantly occurs through close contact with infectious cutaneous or mucosal lesions, respiratory secretions, or contaminated bodily fluids. The natural reservoir of monkeypox virus has not been definitively established; however, several small mammalian species, particularly rodents and squirrels, have been proposed as potential reservoir hosts. Nonhuman primates, including monkeys, and humans are considered incidental or accidental hosts rather than established reservoirs. [8]

Novel transmission pattern:

Zoonotic transmission of monkeypox virus may occur through direct exposure to infected animals or their lesions and bodily fluids, as well as through animal bites or scratches, consumption of contaminated meat, and contact with contaminated materials or fomites. Human-to-human transmission of monkeypox virus primarily occurs through close or prolonged contact with infected individuals, particularly through exposure to respiratory secretions, infectious cutaneous or genital lesions, and contaminated personal items such as clothing and bedding. Although evidence regarding monkeypox virus infection during pregnancy remains limited, available reports provide evidence of vertical transmission, indicating the potential for transplacental spread from mother to fetus. Disseminated cases of monkeypox have been documented in African endemic regions, particularly following close exposure to infected wild animals, with rodents considered an important source of zoonotic transmission. Historically, travel-associated cases identified outside endemic areas resulted in limited secondary transmission, suggesting that sustained human-to-human transmission was relatively inefficient. The unusually high frequency of human-to-human transmission observed during the outbreak highlights close and sustained interpersonal contact as a predominant route of monkeypox virus transmission. A meta-analysis involving 124 reported cases found that sexual contact was implicated in approximately 91% of infections. Consistent with these findings, a large epidemiological analysis of 21,098 monkeypox cases from 41 countries, with data available through 23 August 2022, further highlighted the prominent role of sexual and intimate contact in transmission during the 2022 outbreak. Transmission occurred predominantly through close physical and intimate contact associated with sexual activity. [9]

METHOD:

Suspected cases of monkeypox virus infection were identified through clinical notification and active or passive surveillance conducted by state and local public health authorities. Specimens obtained from individuals presenting with characteristic cutaneous lesions were evaluated at the Centers for Disease Control and Prevention (CDC), Atlanta, Georgia, for evidence of monkeypox virus infection. Laboratory confirmation was established using a combination of diagnostic approaches, including viral culture, polymerase chain reaction (PCR) assays targeting monkeypox virus and orthopoxviruses, electron microscopy, and/or immunohistochemical analysis. emographic characteristics, medical history, smallpox vaccination status, clinical manifestations, disease duration, and laboratory parameters, including hematological and serum biochemical findings, were retrospectively extracted from patient medical records using a standardized data collection instrument. The onset of illness was defined as the date on which a case patient first reported any relevant signs or symptoms, including fever, rash, sweating, chills, lymphadenopathy, headache, neck stiffness, ocular manifestations, rhinorrhea, sore throat, cough, wheezing, dyspnea, chest pain, nausea or vomiting, abdominal pain, myalgia, back pain, arthralgia, confusion, and conjunctivitis. The extent of cutaneous involvement was classified according to World Health Organization criteria as mild (5–25 lesions), moderate (26–100 lesions), severe (101–250 lesions), or very severe (>250 lesions). Data were compiled using Microsoft Access and subsequently analyzed with SAS software, version 8.01 for Windows (SAS Institute). Clinical signs and symptoms were treated as categorical variables, and clinical syndromes were defined by grouping commonly occurring combinations of initial manifestations observed among individual patients. Six routinely assessed laboratory parameters associated with viral infection were evaluated, including leukocytosis, lymphocytosis, thrombocytopenia, elevated transaminase concentrations, increased alkaline phosphatase levels, and hypoalbuminemia. An abnormality threshold was defined as the presence of abnormalities in at least three of these

six laboratory parameters, representing the majority of measurements. This criterion was selected to maximize the number of patients classified above or below the predefined threshold. Hospitalization was defined as an inpatient stay exceeding 48 h in accordance with the established admission criteria, and intensive care unit (ICU) admission was additionally assessed as an indicator of disease severity. Bivariate analyses were conducted to identify factors associated with severe disease, prolonged hospitalization (>48 h), and the presence of three or more abnormal laboratory parameters. Comparative analyses were additionally performed to evaluate differences between pediatric and adult patients and between individuals with and without a history of prior smallpox vaccination. [10]

Diagnostic Strategies and Clinical Differentiation: Diagnosing monkeypox presents notable clinical challenges due to its symptomatic overlap with other viral exanthems, particularly varicella (chickenpox) and variola (smallpox). Although initial clinical evaluation provides key preliminary clues, definitive diagnosis depends on laboratory confirmation to ensure effective public health surveillance and outbreak management.

- **Polymerase Chain Reaction (PCR):** Assays-specifically real-time PCR targeting pan-orthopoxvirus or monkeypox virus-specific genomic sequences-serve as the diagnostic gold standard due to their high sensitivity and specificity.
- **Electron Microscopy:** Although useful for differentiating orthopoxviruses from parapoxviruses, it cannot distinguish between members of the same viral group.
- **Histopathology:** While incapable of species-level viral identification, histopathologic examination aids in differentiating poxvirus lesions from herpesvirus infections.
- **Serology & Isolation:** Complementary methods such as ELISA and viral culture offer reliable confirmation within broader diagnostic workflows.

Furthermore, recent developments in rapid diagnostic technologies have enhanced point-of-care detection, facilitating earlier intervention and improved disease control. [11]

Monkeypox Outbreak in India

India reported the first case of monkeypox in the WHO South-East Asia Region in a 35-year-old man who returned to Kerala from the United Arab Emirates (UAE) with fever and skin rashes. The patient subsequently recovered completely following resolution of the symptoms. Subsequently, 25 cases were reported across several Indian states, including Kerala, New Delhi, Uttar Pradesh, Bihar, Telangana, and Rajasthan, with most cases associated with a history of international travel. One fatality was documented in a 22-year-old man who had been residing in the UAE and reportedly had close contact with a confirmed monkeypox case. After returning to his hometown in Kerala, he developed encephalitis and eventually succumbed to the illness. Although encephalitis has previously been recognized as a potentially fatal neurological complication of monkeypox, its occurrence in immunocompetent individuals remains uncommon. The underlying mechanisms may involve direct viral invasion of the central nervous system or an immune-mediated process, such as myelin oligodendrocyte glycoprotein antibody-associated disease (MOGAD) triggered by viral infection. In the reported case, the clinical presentation and neuroimaging findings favored direct monkeypox virus-associated encephalitis over MOGAD. Nevertheless, MOGAD could not be definitively excluded because serum and cerebrospinal fluid (CSF) samples were unavailable for confirmatory investigations. Other potential infectious causes of encephalitis, including Japanese encephalitis virus, West Nile virus, and Nipah virus, were investigated and excluded. [12]

Complication associated with monkeypox and prevention:

a) Neurological and Psychiatric Complication:

Monkeypox virus infection carries a notable risk of neuro-psychiatric sequelae. A 2020 study in Nigeria revealed that up to 25% of hospitalized patients exhibited psychiatric distress - namely anxiety, depression, and suicidal ideation-though attributing these manifestations solely to viral etiology is complicated by the psychosocial toll of clinical isolation. Neurological manifestations were further documented during the 2022 global outbreak, with incidence rates of 2.7% for seizures, 2.4% for altered mental status (confusion), and 2% for encephalitis. Crucially, the

identification of monkeypox virus - specific IgM antibodies within cerebrospinal fluid (CSF) provides direct immunologic evidence of neuro-invasion. A convenience-sampled online survey of 510 participants conducted in late July 2022 revealed that respondents possessed moderate monkeypox virus knowledge, a neutral attitude toward the disease, and moderate levels of associated anxiety.

b) Dermatological Complications:

Monkeypox virus virus infection is predominantly characterized by cutaneous lesions concentrated in the anogenital region. The clinical course spans two to three weeks, during which 0.5–1 cm lesions transition through distinct stages-from maculopapular beginnings to fluid-filled vesicular and umbilicated pustular phases-ending with complete crusting and healing. Monkeypox is characteristically marked by a distinct cutaneous manifestation, beginning as painful or pruritic maculopapular lesions that sequentially evolve into vesiculopustular eruptions. Although the rash typically presents within 1–3 days after prodromal symptoms develop, its onset can vary - appearing concurrently with fever or standard systemic signs, or after a more prolonged delay. The distribution is predominantly centrifugal, frequently initiating on the face before spreading peripherally to the trunk, extremities, palms, soles, and mucosal membranes, with the highest density of lesions usually clustered on the face and limbs. Additionally, mucosal involvement (enanthems) within the oral cavity may herald the onset of cutaneous lesions. Systemic review data highlight sore throat as the primary reported oral symptom, with mucosal ulceration representing the most prevalent oral and perioral clinical sign. A multicountry study examining 528 monkeypox cases during the 2022 outbreak highlighted anogenital and mucosal involvement as predominant clinical features, present in 73% and 41% of individuals, respectively. While cutaneous rash remained the most pervasive manifestation (95%), systemic symptoms were also widespread, notably fever (62%), lymphadenopathy (56%), lethargy (41%), myalgia (31%), and headache (27%). Given the pleomorphic and changing clinical spectrum of monkeypox, clinicians - particularly dermatologists-must maintain elevated diagnostic suspicion when assessing suspected cases.

c) Complications Associated with Heart (Myocarditis):

Cardiac complications, including myocarditis, pericarditis, and myopericarditis, represent rare clinical manifestations of monkeypox virus infection. In the United States, two unvaccinated, immunocompetent adult patients presented with cardiac symptoms, notably chest pain, alongside elevated cardiac biomarkers secondary to monkeypox-induced myocarditis. Both cases required hospitalization and were treated supportively alongside antiviral (oral tecovirimat) and antibacterial (doxycycline) therapy for the underlying infection. Due to the rapid spontaneous clinical improvement and subsequent normalization of serum troponin levels, targeted cardiovascular interventions were unnecessary, and both patients were successfully discharged without acute sequelae. Diverse viruses, including adenoviruses and Coxsackie viruses, can trigger myocarditis and subsequently lead to dilated cardiomyopathy. The classic histopathological profile consists of lymphocytic myocarditis and myocyte necrosis, typically arising 10 to 14 days post-infection. Historically, myocardial damage resulting from orthopoxvirus infections represents one of the earliest documented cases of viral heart involvement. Although the specific pathways driving orthopoxvirus-induced myocardial inflammation remain under active investigation, clinical evidence indicates that monkeypox infection may precipitate significant cardiovascular pathologies, such as heart failure and conduction abnormalities

d) Hypotension Sepsis Complication:

In severe monkeypox cases, the interplay between systemic inflammation and fluid loss - driven by fever, rash extent, and vascular leakage - frequently leads to hypotension and subsequent acute kidney injury due to reduced renal perfusion. Continuous surveillance of renal function via fluid balance and blood chemistry is therefore crucial. Additionally, secondary bacterial superinfections (e.g., Streptococcus pyogenes) can complicate the disease course, leading to sepsis. Early identification using established criteria is vital, requiring immediate execution of standard sepsis bundles, including hour-one broad-spectrum antibiotics, volume expansion, vasoactive agents, and ventilatory assistance where necessary.

e) Ocular Complication:

Though uncommon, ophthalmic complications such as conjunctivitis, blepharitis, and related ocular inflammation can occur, frequently via self-inoculation. Left unmanaged, these conditions carry a risk of corneal scarring and subsequent visual loss. Ocular manifestations of monkeypox vary in severity, ranging from mild surface inflammation - characterized by conjunctival hyperemia, frontal headaches, periocular eruptions, epiphora, ocular discharge, and subconjunctival nodules-to vision-threatening complications. Although less frequent, severe involvement can lead to keratitis, corneal ulceration, stromal opacification, perforation, and permanent visual loss. Specialist ophthalmologic assessment-utilizing slit-lamp and dilated fundoscopic examinations is essential for evaluating anterior and posterior ocular damage in patients presenting with monkeypox. Therapeutic management emphasizes supportive care, including retinol supplementation, ocular lubricants, and saline compresses, supplemented by targeted antibiotics or antivirals in cases of co-infection. To prevent further complications, contact lens use should be strictly discontinued. Additionally, ophthalmologist-guided administration of topical trifluridine is indicated for keratitis and may be considered for conjunctival involvement.

f) Immune System-Related Complications and Immune Evasion Mechanisms of monkeypox Virus:

Monkeypox virus modulates host immune responses through several mechanisms that facilitate viral survival and replication. Similar to other viral infections, including COVID-19, monkeypox infection has been associated with alterations in cytokine production and immune signaling pathways. The reported cytokine response involves changes in the balance between T-helper 1 (Th1)- and T-helper 2 (Th2)-associated responses, with increased levels of Th2-associated cytokines, including interleukins IL-4, IL-5, IL-6, and IL-10, alongside reduced levels of Th1-associated mediators such as interferon-gamma (IFN-γ), IL-2, and IL-12, as well as tumor necrosis factor-alpha (TNF-α) and interferon-alpha (IFN-α). Such alterations may contribute to impaired antiviral immune activity. Furthermore, monkeypox virus can manipulate host-cell processes through post-translational modifications of cellular proteins and changes in histone regulation, potentially influencing chromatin organization and host–virus interactions. The virus also encodes proteins that interfere with programmed cell death (apoptosis), thereby prolonging host-cell survival and creating favorable conditions for viral replication. Innate immunity, particularly the interferon (IFN) response, represents a critical component of the host's initial defense against viral infections. Interferons restrict viral replication through direct antiviral effects and the activation of intracellular signaling pathways. Type I interferons, including IFN-α, IFN-β, and IFN-ω, initiate antiviral responses primarily through the Janus kinase–signal transducer and activator of transcription (JAK–STAT) signaling pathway. However, monkeypox virus has evolved several strategies to counteract these defenses. An *in vitro* investigation reported that the viral protein B16 interferes with type I IFN-induced JAK–STAT signaling, thereby potentially weakening interferon-mediated antiviral activity. In addition, studies in mice have indicated that D7L homologues can inhibit IL-18 activity, further modulating host immune responses. The virus also produces a complement control protein (CCP) that interferes with complement activation, an important component of innate immune defense. Beyond these mechanisms, monkeypox virus expresses a diverse repertoire of immunomodulatory proteins that target multiple components of host immunity. These include ankyrin-like proteins, viral growth factors, IL-18-binding proteins, apoptosis inhibitors, and serine protease inhibitors such as SPI-1. Other viral factors interfere with major histocompatibility complex (MHC) class I and class II antigen presentation, inhibit the activation of interferon regulatory factors (IRF3 and IRF7) and nuclear factor kappa B (NF-κB), and bind CC and CXC chemokines. Collectively, these immune-evasion strategies can disrupt cytokine signaling, antigen presentation, inflammatory responses, and antiviral defense mechanisms, thereby facilitating monkeypox virus replication and persistence within the host.[13]

Treatment of monkeypox:

The management of monkeypox primarily involves supportive and symptomatic care, including adequate nutrition, hydration, monitoring for secondary infections, and prompt administration of appropriate antibiotics when bacterial complications arise. Although

several antiviral agents have been investigated for monkeypox, their clinical effectiveness and safety profiles vary. Cidofovir, a nucleotide analogue that inhibits viral DNA polymerase, has demonstrated in vitro activity against orthopoxviruses; however, its clinical use is limited by significant nephrotoxicity. Brincidofovir (CMX001), an orally available lipid-conjugated derivative of cidofovir, was developed to improve tolerability and reduce renal toxicity. Nevertheless, limited clinical evidence has shown inconsistent responses to cidofovir-based treatment in patients with mpox. Tecovirimat (ST-246; TPOXX®) is an antiviral agent that targets the orthopoxvirus VP37 envelope-associated protein, thereby inhibiting the formation and release of infectious viral particles and limiting viral dissemination between cells. The drug has demonstrated protective efficacy in animal models of orthopoxvirus infection and has generally been well tolerated. It has been authorized for specific orthopoxvirus-related indications in several regions; however, its approval status and recommendations for monkeypox treatment differ among countries and may change as further evidence becomes available. Tecovirimat has been considered particularly relevant for patients with severe disease or an increased risk of complications, including immunocompromised individuals and pregnant patients, although treatment decisions should be guided by current national guidelines and clinical assessment. Vaccinia immune globulin intravenous (VIGIV), derived from the plasma of individuals vaccinated against vaccinia virus, has historically been used to manage certain complications associated with smallpox vaccination. Its potential role in monkeypox remains limited, and evidence supporting its routine use is insufficient. Antiviral treatment may be considered for patients with severe or progressive disease and those at increased risk of adverse outcomes, depending on the availability of effective therapies and applicable treatment guidelines. Antibiotics are indicated when secondary bacterial infections occur rather than as routine treatment for the viral infection itself. Clinical reports have described relatively limited use of antiviral agents among patients with monkeypox, including tecovirimat, cidofovir, and vaccinia immune globulin. Adverse clinical events have also been reported during treatment; however, the temporal association between treatment and an event does not necessarily establish causality. Overall, further clinical research is required to clarify the efficacy, safety, and optimal use of antiviral therapies in monkeypox management.[14]

Vaccination and Treatment:

Several antiviral agents and vaccines have been investigated for the prevention and management of monkeypox. Among the therapeutic agents, tecovirimat has been authorized for specific indications in the United States and Europe, whereas brincidofovir has received authorization in the United States for other orthopoxvirus-related indications. Tecovirimat inhibits the orthopoxvirus protein p37, which is essential for the formation and release of infectious viral particles, thereby limiting the spread of the virus between cells. Although the drug is approved by the U.S. Food and Drug Administration (FDA) for smallpox treatment, its use against monkeypox has historically been evaluated under an investigational new drug (IND) protocol rather than through full regulatory approval for this indication. Preclinical studies, including four major investigations in nonhuman primates, demonstrated promising protective effects, with tecovirimat reducing mortality by approximately 95% compared with placebo. Its safety and tolerability have also been examined in Phase I and Phase II clinical trials. Additionally, preliminary findings from a small observational study suggested that tecovirimat might reduce the duration of viral shedding and clinical illness in patients with monkeypox; however, these observations require validation through larger, well-designed clinical trials. Brincidofovir is another antiviral agent that acts by inhibiting viral DNA polymerase, thereby interfering with viral genome replication. Its potential therapeutic efficacy has been supported by animal studies, particularly those involving murine and rabbit models, in which improved survival outcomes were observed following infection. Evidence regarding its safety in humans has primarily been derived from clinical trials conducted for cytomegalovirus disease in recipients of hematopoietic stem-cell transplants. Nevertheless, its clinical application may be limited by gastrointestinal adverse effects and hepatotoxicity, which raise concerns regarding its tolerability compared with tecovirimat. Despite the encouraging findings from preclinical and early clinical investigations, further randomized controlled trials are required to establish the efficacy and

safety of antiviral therapies for monkeypox. The World Health Organization (WHO), in collaboration with several countries, has supported clinical investigations to assess these treatments, with particular attention directed toward tecovirimat. Such studies should include populations from both endemic regions and areas affected by ongoing outbreaks to establish the generalizability of treatment outcomes. The development of alternative therapeutic agents is also important, particularly in view of the potential emergence of antiviral resistance and the need for effective second-line treatment options. Vaccinia immune globulin represents an additional therapeutic intervention and consists of purified gamma globulins derived from the plasma of individuals immunized with live vaccinia virus. In the United States, it is licensed for the management of certain complications arising from smallpox vaccination. Research into alternative therapeutic strategies has also focused on novel antiviral compounds and monoclonal antibodies. NIOCH-14, a synthetic compound related to tecovirimat, has completed Phase I clinical evaluation. In parallel, several monoclonal antibodies targeting orthopoxviruses are under investigation, with some candidates having advanced to preclinical testing. These approaches may contribute to the development of additional therapeutic options in the future. Vaccination remains an important component of monkeypox prevention and outbreak control. The principal vaccines discussed in this context include ACAM2000 and MVA-BN. ACAM2000, developed by Emergent Biosolutions, is a second-generation live vaccinia virus vaccine authorized by the FDA for smallpox prevention and relevant orthopoxvirus indications. Although it can provide protection against orthopoxvirus infection, its use is associated with potentially serious adverse events, including cardiac complications. MVA-BN, developed by Bavarian Nordic, is a third-generation vaccine based on modified vaccinia Ankara (MVA). Unlike replication-competent vaccinia vaccines, MVA-BN contains a live but nonreplicating virus, providing a different safety profile. It has been authorized for smallpox prevention in the United States and Europe and received FDA approval for mpox prevention in 2019. LC16m8, developed by KM Biologics, is another third-generation vaccine containing a highly attenuated vaccinia virus. Although licensed for smallpox prevention in certain settings, its authorization for monkeypox prevention has differed across jurisdictions. MVA-BN has also been granted emergency authorization by several national regulatory authorities, including France, for post-exposure prophylaxis against monkeypox. This has supported the implementation of ring-vaccination programmes, in which close contacts and other individuals at elevated risk are prioritized for vaccination following identification of a confirmed case. In response to increasing case numbers and the practical limitations of timely diagnosis and contact tracing, some countries, including the United Kingdom and France, have additionally recommended third-generation smallpox vaccines for individuals with an increased likelihood of exposure. Such targeted vaccination strategies may help reduce transmission, particularly when combined with surveillance, early diagnosis, contact tracing, and appropriate clinical management. [15]

CONCLUSION:

Monkeypox has transitioned from a localized zoonotic disease to a global public health priority, underscoring the urgent necessity for coordinated international response frameworks. Understanding the complex genomic architecture, cytoplasmic replication cycle, and multifaceted immune - evasion mechanisms of the virus provides essential foundations for targeted therapeutic development. While accurate molecular diagnostics like PCR enable early detection, managing severe clinical manifestations - ranging from extensive cutaneous lesions to critical neurological, cardiovascular, and ocular complications - demands comprehensive care alongside specialized antiviral agents such as tecovirimat and brincidofovir. Furthermore, strategically deployed second - and third-generation vaccines (e.g., MVA-BN, ACAM2000) remain paramount in containment through ring-vaccination strategies. To effectively mitigate future resurgences, continued clinical trials, robust epidemiological surveillance, enhanced global access to medical countermeasures, and expanded research into novel therapeutics and second-line interventions are vital.

REFERENCES

1. Yamin Ansari*, Ashwini Pawar, Krutika Channe, Vinod Thakare, Understanding Monkey pox: A Comparative Analysis with Other

Poxviruses and Environmental Influences, Int. J. of Pharm. Sci., 2025, Vol 3, Issue 1, 371-379.

2. Letafati A, Sakhavarz T. Monkeypox virus: A review. Microb Pathog. 2023 Mar; 176:106027.
3. Mitjà O, Ogoina D, Titanji BK, Galvan C, Muyembe JJ, Marks M, Orkin CM. Monkeypox. The Lancet. 2023 Jan 7;401 (10370):60-74.
4. Yahya G, Mohamed NH, Wadan AS, Castro EM, Kamel A, Abdelmoaty AA, Alsadik ME, Martinez-Sobrido L, Mostafa A. The Emerging Threat of Monkeypox: An Updated Overview. Viruses. 2026 Jan 3;18 (1):69.
5. Elsayed S, Bondy L, Hanage WP. Monkeypox Virus Infections in Humans. Clin Microbiol Rev. 2022 Dec 21;35 (4): e0009222.
6. Sabafarin Shaikh, Pratiksha Udawant, Khare Komal, Mayur S. Bhosle, Sushmita Chavan, Review Of Monkeypox Virus: Symptoms, Pathogenesis, Diagnosis And Treatment, Int. J. of Pharm. Sci., 2024, Vol 2, Issue 1, 298-310.
7. Asadi Noghabi F, G Rizk J, Makkar D, Roozbeh N, Ghelichpour S, Zarei A. Managing Monkeypox Virus Infections: A Contemporary Review. Iran J Med Sci. 2024 Jan 1;49 (1):1-9.
8. Farahat RA, Sah R, El-Sakka AA, Benmelouka AY, Kundu M, Labieb F, Shaheen RS, Abdelaal A, Abdelazeem B, Bonilla-Aldana DK, Franco-Paredes C, Henao-Martinez AF, Garout MA, León-Figueroa DA, Pachar M, Suárez JA, Ramirez JD, Paniz-Mondolfi A, Rabaan AA, Al-Tawfiq JA, Nishiura H, Ortiz-Martínez Y, Garcia-Robledo JE, Cimerman S, Barbosa AN, Pagliano P, Zambrano-Sanchez G, Cardona-Ospina JA, Bížová B, Rodriguez-Morales AJ. Human monkeypox disease (MPX). Infez Med. 2022 Sep 1;30 (3):372-391.
9. Huang, Y., Mu, L. & Wang, W. Monkeypox: epidemiology, pathogenesis, treatment and prevention. *Sig Transduct Target Ther* 7, 373 (2022).
10. Gregory D. Huhn, Audrey M. Bauer, Krista Yorita, Mary Beth Graham, James Sejvar, Anna Likos, Inger K. Damon, Mary G. Reynolds, Matthew J. Kuehnert, Clinical Characteristics of Human Monkeypox, and Risk Factors for Severe Disease, *Clinical Infectious Diseases*, Volume 41, Issue 12, 15 December 2005, Pages 1742–1751.
11. Ankita Singh, Suraj Kumar, Jiten Goray, Shivam Kashyap, Gangadhar Singh, Sudarshan Rawani, Priyanshu Kumar Singh, Ayush Kumar Verma, Rashmi Kumari, Purnima Kumari, Nisha Kumari, Anisha Kumari, Sweta Verma, Megha Chattaraj, Prince Verma, Arnab Roy*, Dr. K. Rajeswar Dutt, Global Monkeypox Outbreak: Lessons Learned and Future Direction, Int. J. of Pharm. Sci., 2024, Vol 2, Issue 12, 2547-2558.
12. Krishna S, Kurrey C, Yadav M, Mahilkar S, Sonkar SC, Vishvakarma NK, Sonkar A, Chandra L, Koner BC. Insights into the emergence and evolution of monkeypox virus: Historical perspectives, epidemiology, genetic diversity, transmission, and preventative measures. Infectious medicine. 2024 Jun 1;3 (2):100105.
13. Yadav R, Chaudhary AA, Srivastava U, Gupta S, Rustagi S, Rudayni HA, Kashyap VK, Kumar S. Mpox 2022 to 2025 update: A comprehensive review on its complications, transmission, diagnosis, and treatment. Viruses. 2025 May 25;17 (6):753.
14. Laxmi Patil*, Sachin Kamble, Pratik Kadere, Mahesh Manke, Mpox: The New Revolutionary For World:2024, Int. J. of Pharm. Sci., 2024, Vol 2, Issue 10, 1817-1823.
15. Gessain A, Nakoune E, Yazdanpanah Y. Monkeypox. N Engl J Med. 2022 Oct 26;387 (19):1783-93.

Cite: Shashank K., Bhanunandana G. S., Bhargav Shankar Naik, Smithan B. R., Dr. *M. Mallikarjuna* Gouda, Monkeypox Virus: From Viral Pathogenesis and Transmission Dynamics to Emerging Therapeutics and Vaccines, Int. J. Med. Pharm. Sci., 2026, 2 (11), 276-288. https://doi.org/10.5281/zenodo.24579676